Prostate Focal Therapy

Alice Yu, MD, MPH

Nikki Little, MSN, APRN, FNP-C

MOFFITT CANCER CENTER

Disclosures

Alice Yu - Angiodynamics, Novo Nordisk

Nikki Little – Speaker Bureau with Lantheus and Advisory Board with Cardinal Health during the last 24 months.

Localized Prostate Cancer Treatment

Radical Prostatectomy

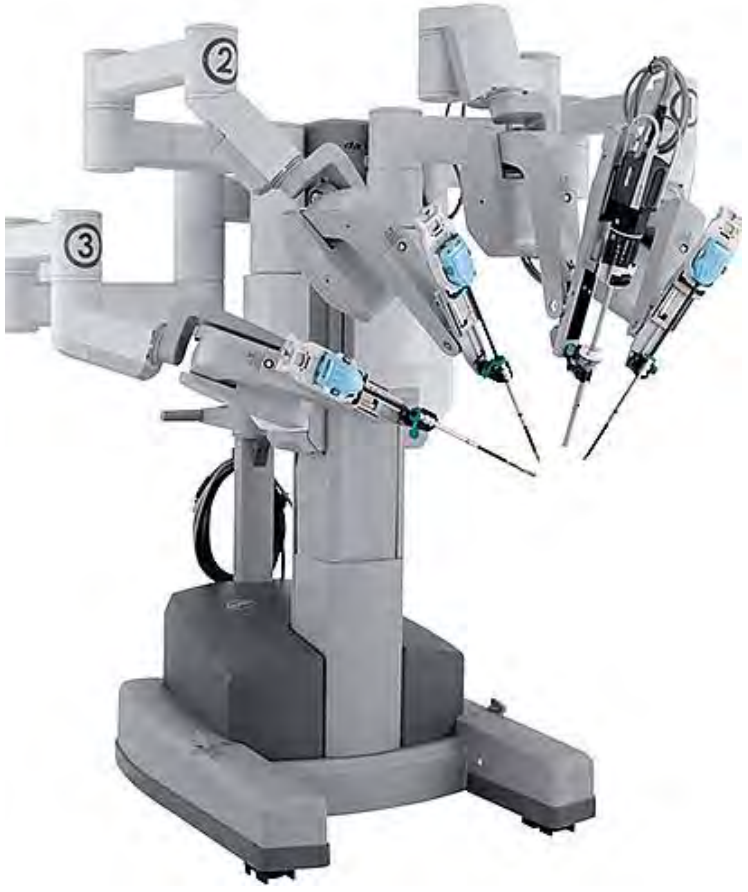

Radiation Therapy

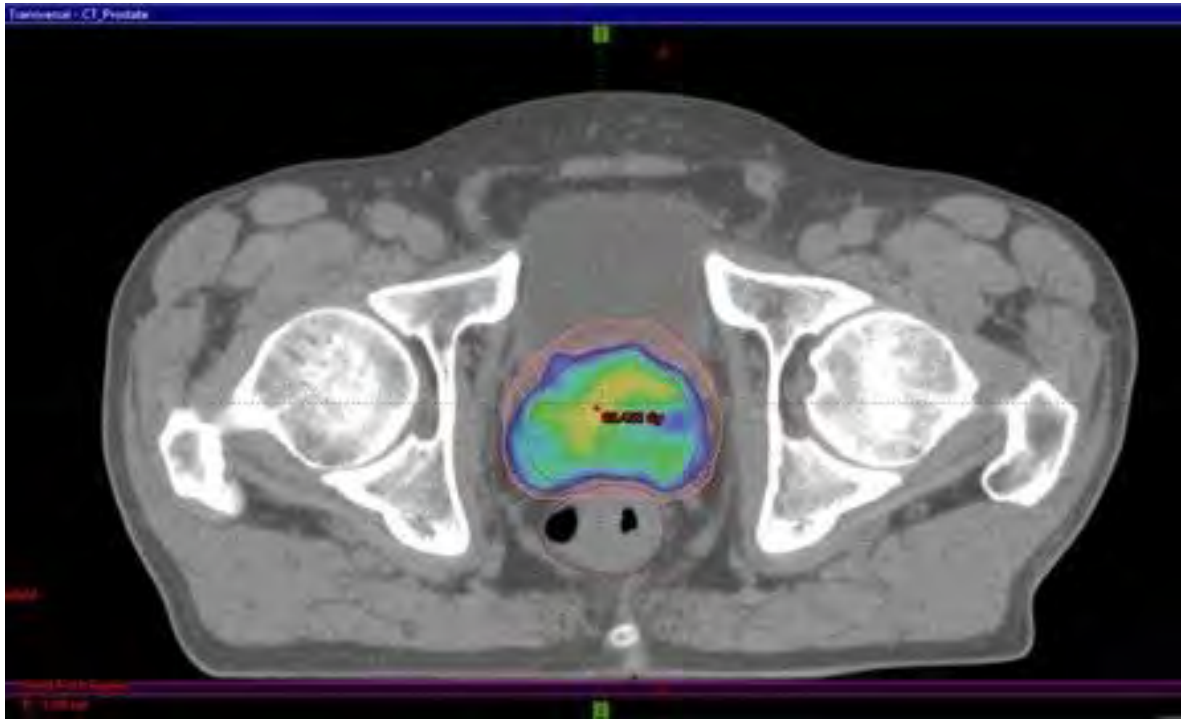

Side Effects

- Surgical risks
- Urinary incontinence
- Erectile dysfunction

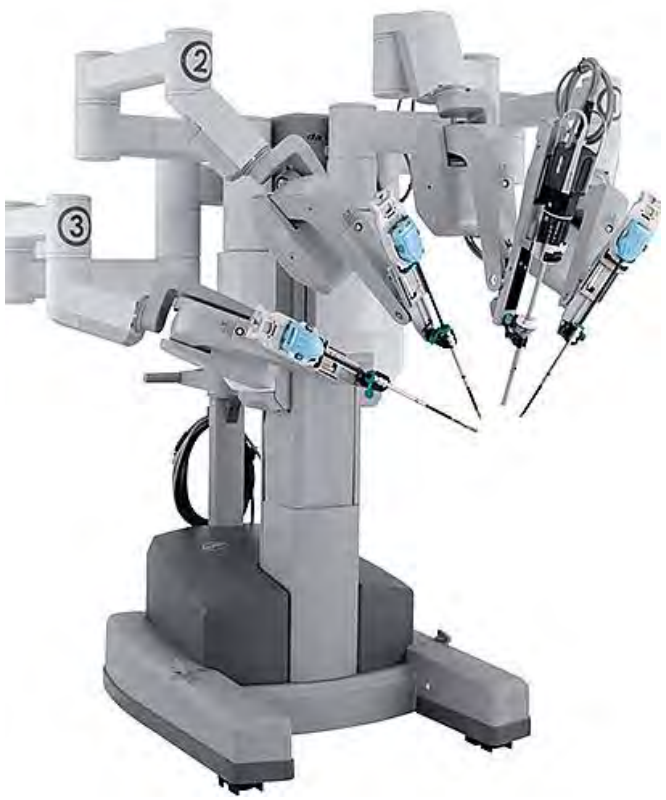

- Radiation cystitis
- GI effects
- Proctitis
- Secondary malignancy

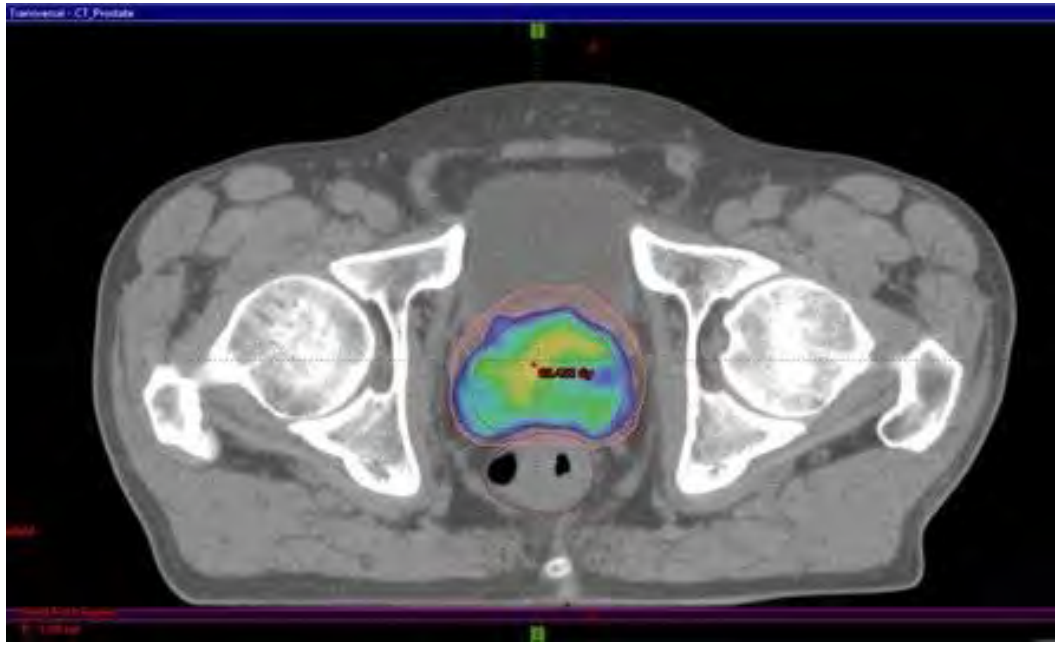

Treatment Dogma

- Prostate cancer is multifocal
- Treat the entire gland

Prostate Cancer is Multifocal?

- 15% of patients have unifocal tumors
- The index lesion drives metastatic spread

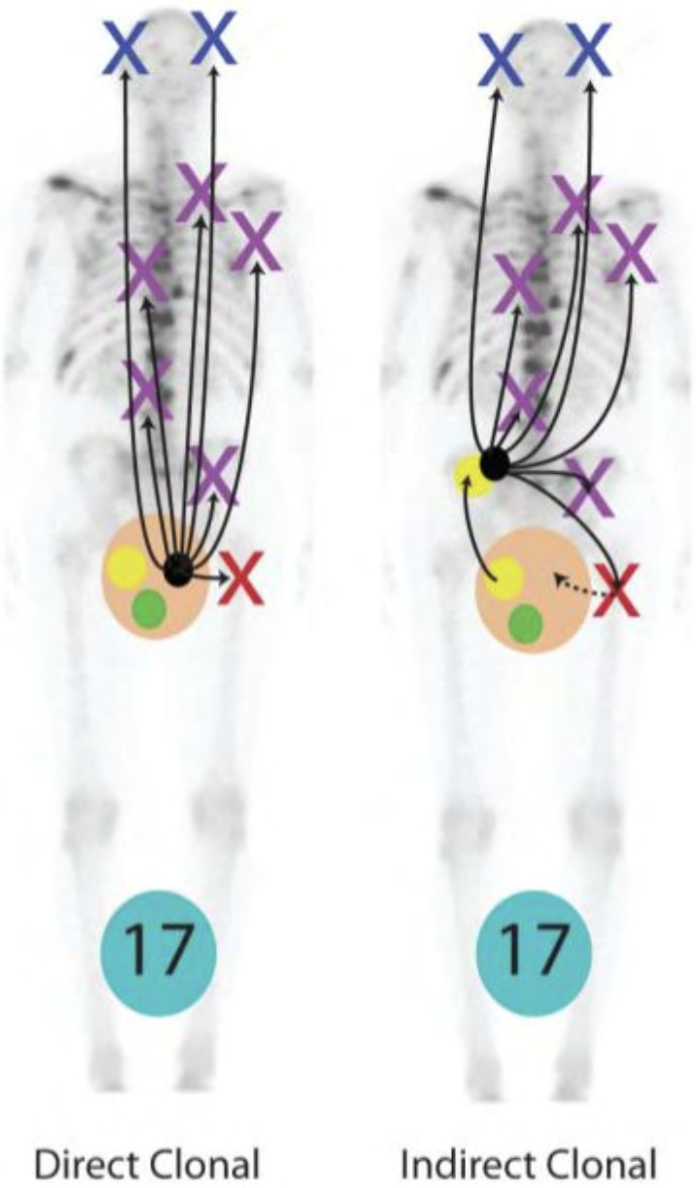

Masterson et al. BJU Int 2011
Liu et al. Nat Med 2009

Organ sparing treatment is utilized in many types of cancer

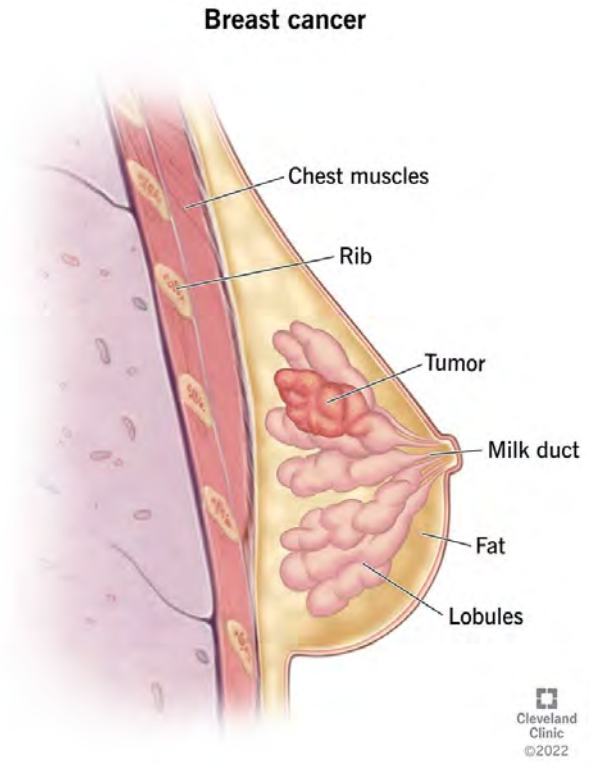

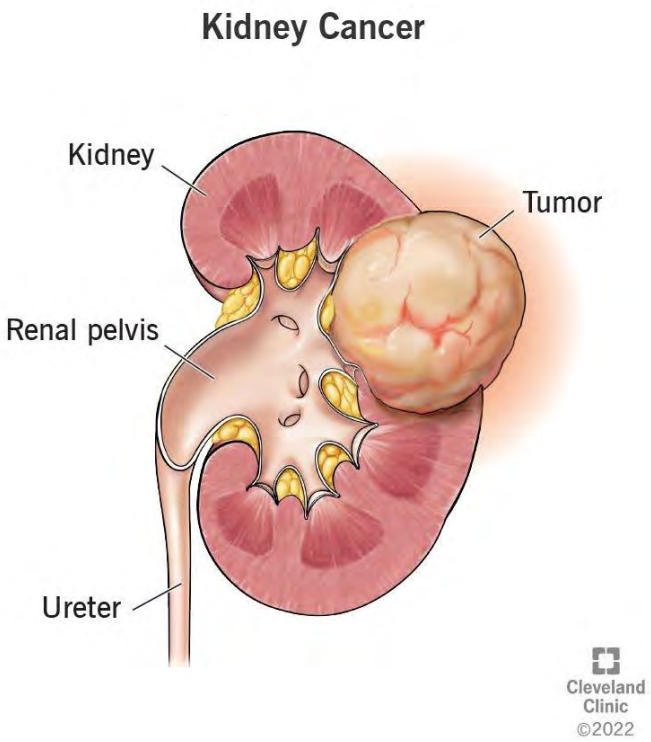

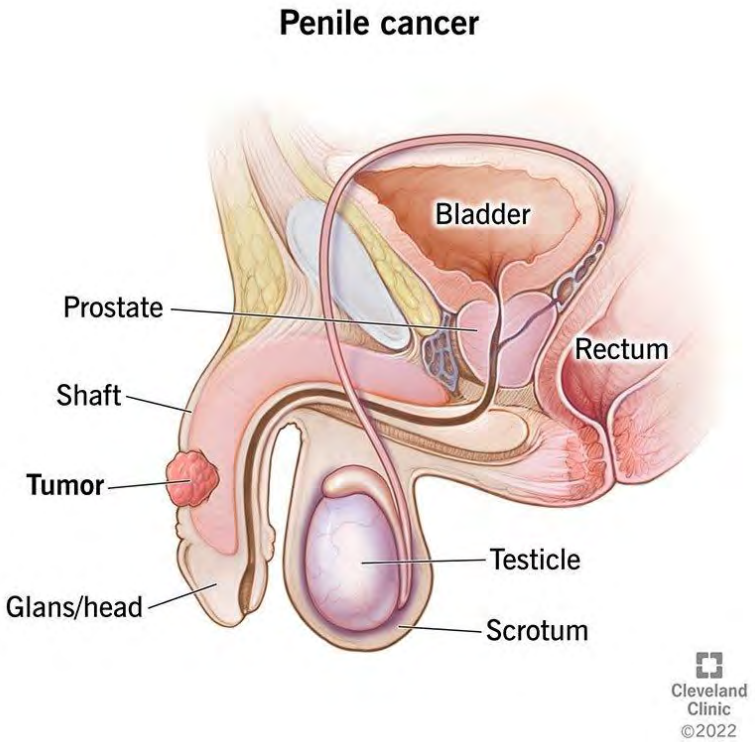

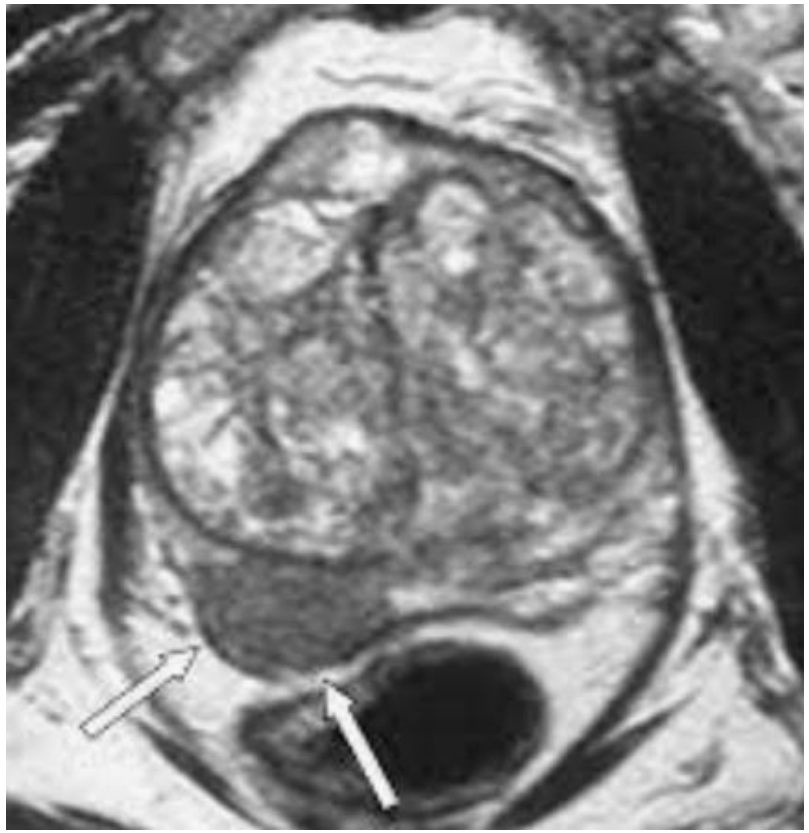

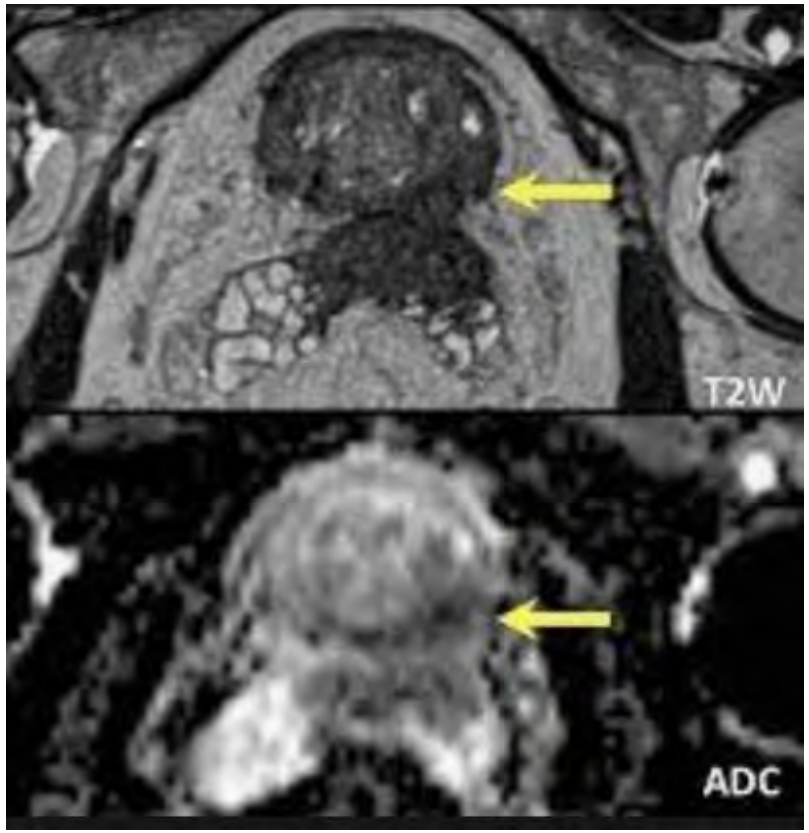

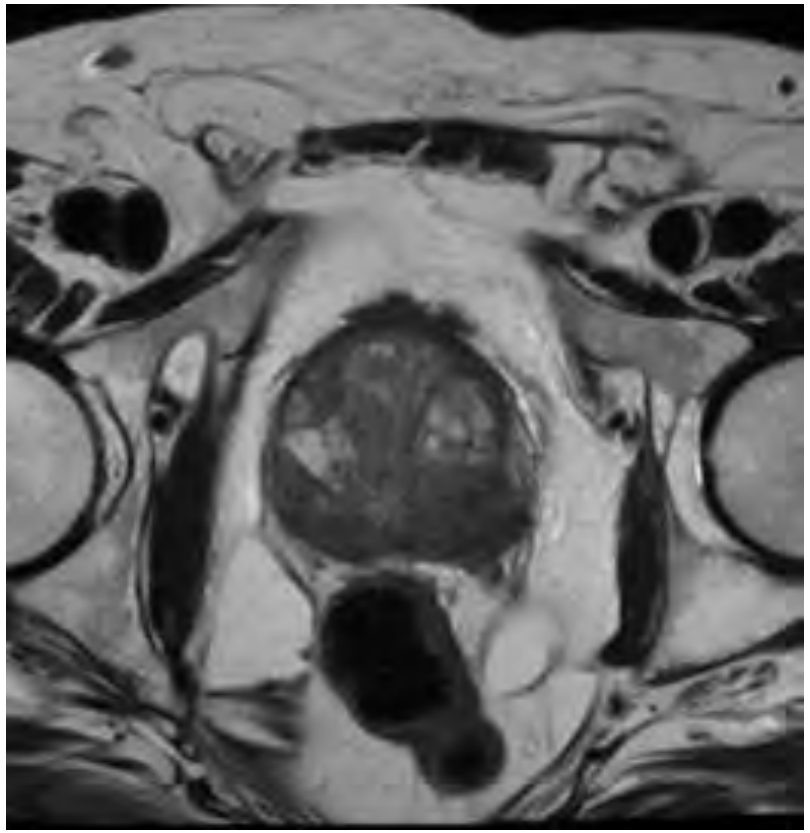

Index Lesion

Focal Therapy

- Achieve oncologic control
- Improve urinary and sexual function side effects

Focal Therapy Modalities

Cryotherapy **COLD**
High-intensity focused ultrasound (HIFU) **HEAT**
Transurethral ultrasound ablation (TULSA)
Focal laser ablation (FLA)
Vascular-targeted photodynamic therapy (VTP) **OXYGEN FREE RADICALS**
Irreversible electroporation **ELECTRICAL PULSES**
Radiofrequency ablation (RFA)
Focal radiation/brachytherapy
Laser interstitial thermotherapy
Gold-silica nanoshells (GSNs)
Microwave therapy

Cryotherapy

- First used in 1964 by Gonder et al. using liquid nitrogen placed through the urethra
  - Unable to monitor the needle placement
  - Many complications (incontinence, urethral sloughing, rectourethral fistulas)
- 1980's Onik et al. refined the technique
  - Used TRUS for accurate placement of cryoprobes with real-time monitoring
  - Used urethral warming catheter
- Argon gas for freezing and Helium gas for thawing
- Real-time temperature monitoring probes

Table 1 – Results of primary cryosurgery

Ref. (with actuarial data)	No. patients	Median follow-up in months (range)	Technique	PSA threshold	Low risk	bDFS (%) Intermediate risk	High risk[a]	nADT (%)	Duplication[b] data: y/n (reference)
Long et al. [16] (5-year data)	975	24 (SD ± 16.5)	LN/Ar	<0.5	60	61	36	33	y (15)
				<1.0	76	71	45		
Donnelly et al. [17] (5-year data)	76	61 (35–85)	LN	<0.3	60	77	48	34	y (19)
				<1.0	75	89	76		
Bahn et al. [15] (7-year data)	590	68 (NA)	LN/Ar	<0.5	61	68	61	91	y (16, 19)
				<1.0	87	79	71		
				ASTRO	92	89	89		
Ellis et al. [65] (3-month data)	75	3 (NA)	Ar	<0.4	84 (all risk groups)			NA	n
Han et al. [12] (1-year data)	122	12 (NA)	Ar	<0.4	78	NA	71	37	n
Cytron et al. [66] (NA)	23	11 (mean) (9–18)	Ar	<0.5	78 (all risk groups)			NA	n
Prepelica et al. [18] (6-year data)	65	35 (4–77)	Ar	ASTRO	83 (most high risk)			68	y (19)
Creswell et al. [14] (1-year data)	31	9 (1.5–18)	Ar	<0.5	60	NA	60	NA	n
Polascik et al. [67] (NA)	50	18 (3–43)	Ar	<0.5	90 (all risk groups)			26	n
Jones et al. [19] (5-year data)	1198	24 (SD ± 26)	LN/Ar	ASTRO	85	73	75	NA	y (15, 17, 18)
				Phoenix	91	79	62		
Hubosky et al. [68] (2-year data)	89	11 (1–32)	Ar	<0.4	74	70	60	35	n
				ASTRO	94 (all risk groups)				
Cohen et al. [62] (10-year data)	204	12.6 (9.7-15.0)	LN	ASTRO	56 (all risk groups)			0	n
				Phoenix	81	74	46		
Chin et al. [23] (4-year data)	33	19 (NA)	Ar	ASTRO	13 (all risk groups)			100	n
				Houston	36 (all risk groups)				

[a] d'Amico risk stratification (1992 American Joint Committee on Cancer): low risk = PSA < 10 ng/ml and Gleason biopsy ≤ 6 and clinical stage T1c–T2a; intermediate risk = PSA 10–20 ng/ml or Gleason biopsy 7 or clinical stage T2b; high risk = PSA > 20 ng/ml or Gleason biopsy ≥ 8 or clinical stage ≥ T2c; nADT, neoadjuvant androgen deprivation therapy.

[b] Duplication of reporting some patient data likely: yes or no (reference); NA, not available; SD, standard deviation; LN, liquid nitrogen; Ar, argon gas; bDFS, biochemical disease free survival; ASTRO = three successive rises in PSA; Houston/Phoenix = PSA 2 ng/ml above nadir.

- Pre-MRI era
- Whole gland vs focal treatment
- No routine post-procedure biopsy
- ASTRO/Phoenix criteria for BCR
- Many patients with low-risk disease
- Some patients with high-risk disease
- Short follow-up

Only FDA approved modality for treatment of prostate **CANCER**

Focal therapy developed a bad reputation

- The ideal patient for focal therapy
  - Low volume intermediate risk (no EPE, no SVI)
  - Visible on MRI
  - Biopsy consistent with MRI findings

HIFU

- Rectal probe with transducer produce high-intensity beam
- Tissue damage through hyperthermia and cavitation
- Rectal mucosa is actively cooled avoid thermal damage

Design: **Prospective**

Median Age: **66**

Study Size: **N = 1379**

Pre-HIFU Median PSA: **6.9**

- Patient follow-up recorded in the HIFU Evaluation and Assessment of Treatment (HEAT) Registry from 13 UK Centers between 2005 –2020
- **>5 years** of follow-up was available for **24%** of patients
- Median follow**: 32 months**
- D'Amico **intermediate-risk in 65%**
- D'Amico **high-risk in 28%**

available at www.sciencedirect.com
journal homepage: www.europeanurology.com

European Association of Urology

Prostate Cancer

Cancer Control Outcomes Following Focal Therapy Using High-intensity Focused Ultrasound in 1379 Men with Nonmetastatic Prostate Cancer: A Multi-institute 15-year Experience

Deepika Reddy[a,b,], Max Peters[c], Taimur T. Shah[a,b], Marieke van Son[c], Mariana Bertoncelli Tanaka[b], Philipp M. Huber[d], Derek Lomas[e], Arnas Rakauskas[f], Saiful Miah[g], David Eldred-Evans[a], Stephanie Guillaumier[h,i], Feargus Hosking-Jervis[a], Ryan Engle[a], Tim Dudderidge[j], Richard G. Hindley[k,l], Amr Emara[k,x], Raj Nigam[m,n], Neil McCartan[h,i], Massimo Valerio[f], Naveed Afzal[o], Henry Lewi[p], Clement Orczyk[h,i], Chris Ogden[q], Iqbal Shergill[r], Raj Persad[s], Jaspal Virdi[t], Caroline M. Moore[h,i,u,v], Manit Arya[b,h,i], Mathias Winkler[a,b], Mark Emberton[h,i,u,v,|], Hashim U. Ahmed[a,b,v,w,|]*

[a] Imperial Prostate, Division of Surgery, Department of Surgery and Cancer, Imperial College London, London, UK; [b] Imperial Urology, Charing Cross Hospital, Imperial College Healthcare NHS Trust, London, UK; [c] Department of Radiation Oncology, University Medical Centre, Utrecht, The Netherlands; [d] Urologie St. Anna, Luzern, Switzerland; [e] Department of Urology, Mayo Clinic, Rochester, MN, USA; [f] Urology Department, Lausanne University Hospital, Lausanne, Switzerland; [g] Department of Urology, Buckinghamshire Hospitals NHS Trust, Amersham, UK; [h] Department of Surgery and Interventional Sciences, University College London, London, UK; [i] University College Hospital, London, UK; [j] Department of Urology, University Hospital Southampton NHS Trust, Southampton, UK; [k] Department of Urology, Basingstoke and North Hampshire Hospital, Hampshire Hospitals NHS Foundation Trust, Basingstoke, UK; [l] BMI The Hampshire Clinic, Basingstoke, UK; [m] Department of Urology, Royal Surrey NHS Foundation Trust, UK; [n] BMI Mount Alvernia Hospital, Guildford, UK; [o] Dorset County Hospital Foundation Trust, Dorchester, UK; [p] Springfield Hospital, Chelmsford, UK; [q] Department of Academic Urology, The Royal Marsden Hospital NHS Foundation Trust, London, UK; [r] Department of Urology, Wrexham Maelor Hospital, Wrexham, UK; [s] North Bristol NHS Trust, Westbury on Trym, Bristol, UK; [t] Department of Urology, The Princess Alexandra Hospital NHS Trust, Harlow, UK; [u] Princess Grace Hospital, London, UK; [v] King Edward VII Hospital, London, UK; [w] Cromwell Hospital, London, UK; [x] Department of Urology, Ain Shams University Hospitals, Cairo, Egypt

Design: **Prospective**

Median Age: **66**

Study Size: **N = 1379**

Pre-HIFU Median PSA: **6.9**

- Repeat focal treatment due to residual or recurrent cancer was required in 252 patients
- Whole-gland salvage was required in 92 patients
- At 7 years
  - 43% retreatment-free
  - 69% failure-free (whole gland tx)
  - No metastasis

available at www.sciencedirect.com
journal homepage: www.europeanurology.com

European Association of Urology

Prostate Cancer

Cancer Control Outcomes Following Focal Therapy Using High-intensity Focused Ultrasound in 1379 Men with Nonmetastatic Prostate Cancer: A Multi-institute 15-year Experience

Deepika Reddy[a,b,], Max Peters[c], Taimur T. Shah[a,b], Marieke van Son[c], Mariana Bertoncelli Tanaka[b], Philipp M. Huber[d], Derek Lomas[e], Arnas Rakauskas[f], Saiful Miah[g], David Eldred-Evans[a], Stephanie Guillaumier[h,i], Feargus Hosking-Jervis[a], Ryan Engle[a], Tim Dudderidge[j], Richard G. Hindley[k,l], Amr Emara[k,x], Raj Nigam[m,n], Neil McCartan[h,i], Massimo Valerio[f], Naveed Afzal[o], Henry Lewi[p], Clement Orczyk[h,i], Chris Ogden[q], Iqbal Shergill[r], Raj Persad[s], Jaspal Virdi[t], Caroline M. Moore[h,i,u,v], Manit Arya[b,h,i], Mathias Winkler[a,b], Mark Emberton[h,i,u,v,†], Hashim U. Ahmed[a,b,v,w,‡]*

[a] Imperial Prostate, Division of Surgery, Department of Surgery and Cancer, Imperial College London, London, UK; [b] Imperial Urology, Charing Cross Hospital, Imperial College Healthcare NHS Trust, London, UK; [c] Department of Radiation Oncology, University Medical Centre, Utrecht, The Netherlands; [d] Urologie St. Anna, Luzern, Switzerland; [e] Department of Urology, Mayo Clinic, Rochester, MN, USA; [f] Urology Department, Lausanne University Hospital, Lausanne, Switzerland; [g] Department of Urology, Buckinghamshire Hospitals NHS Trust, Amersham, UK; [h] Department of Surgery and Interventional Sciences, University College London, London, UK; [i] University College Hospital, London, UK; [j] Department of Urology, University Hospital Southampton NHS Trust, Southampton, UK; [k] Department of Urology, Basingstoke and North Hampshire Hospital, Hampshire Hospitals NHS Foundation Trust, Basingstoke, UK; [l] BMI The Hampshire Clinic, Basingstoke, UK; [m] Department of Urology, Royal Surrey NHS Foundation Trust, UK; [n] BMI Mount Alvernia Hospital, Guildford, UK; [o] Dorset County Hospital Foundation Trust, Dorchester, UK; [p] Springfield Hospital, Chelmsford, UK; [q] Department of Academic Urology, The Royal Marsden Hospital NHS Foundation Trust, London, UK; [r] Department of Urology, Wrexham Maelor Hospital, Wrexham, UK; [s] North Bristol NHS Trust, Westbury on Trym, Bristol, UK; [t] Department of Urology, The Princess Alexandra Hospital NHS Trust, Harlow, UK; [u] Princess Grace Hospital, London, UK; [v] King Edward VII Hospital, London, UK; [w] Cromwell Hospital, London, UK; [x] Department of Urology, Ain Shams University Hospitals, Cairo, Egypt

Design: **Prospective**

Median Age: **66**

Study Size: **N = 1379**

Pre-HIFU Median PSA: **6.9**

- 6% complications
  - 4.6% UTI/epidydimo-orchitis
  - 0.7% urinary retention
  - 0.1% rectorurethral fistula; epididymo-orchitis
    - Two cases

available at www.sciencedirect.com
journal homepage: www.europeanurology.com

European Association of Urology

Prostate Cancer

Cancer Control Outcomes Following Focal Therapy Using High-intensity Focused Ultrasound in 1379 Men with Nonmetastatic Prostate Cancer: A Multi-institute 15-year Experience

Deepika Reddy[a,b,], Max Peters[c], Taimur T. Shah[a,b], Marieke van Son[c], Mariana Bertoncelli Tanaka[b], Philipp M. Huber[d], Derek Lomas[e], Arnas Rakauskas[f], Saiful Miah[g], David Eldred-Evans[a], Stephanie Guillaumier[h,i], Feargus Hosking-Jervis[a], Ryan Engle[a], Tim Dudderidge[j], Richard G. Hindley[k,l], Amr Emara[k,x], Raj Nigam[m,n], Neil McCartan[h,i], Massimo Valerio[f], Naveed Afzal[o], Henry Lewi[p], Clement Orczyk[h,i], Chris Ogden[q], Iqbal Shergill[r], Raj Persad[s], Jaspal Virdi[t], Caroline M. Moore[h,i,u,v], Manit Arya[b,h,i], Mathias Winkler[a,b], Mark Emberton[h,i,u,v,|], Hashim U. Ahmed[a,b,v,w,|]*

[a] Imperial Prostate, Division of Surgery, Department of Surgery and Cancer, Imperial College London, London, UK; [b] Imperial Urology, Charing Cross Hospital, Imperial College Healthcare NHS Trust, London, UK; [c] Department of Radiation Oncology, University Medical Centre, Utrecht, The Netherlands; [d] Urologie St. Anna, Luzern, Switzerland; [e] Department of Urology, Mayo Clinic, Rochester, MN, USA; [f] Urology Department, Lausanne University Hospital, Lausanne, Switzerland; [g] Department of Urology, Buckinghamshire Hospitals NHS Trust, Amersham, UK; [h] Department of Surgery and Interventional Sciences, University College London, London, UK; [i] University College Hospital, London, UK; [j] Department of Urology, University Hospital Southampton NHS Trust, Southampton, UK; [k] Department of Urology, Basingstoke and North Hampshire Hospital, Hampshire Hospitals NHS Foundation Trust, Basingstoke, UK; [l] BMI The Hampshire Clinic, Basingstoke, UK; [m] Department of Urology, Royal Surrey NHS Foundation Trust, UK; [n] BMI Mount Alvernia Hospital, Guildford, UK; [o] Dorset County Hospital Foundation Trust, Dorchester, UK; [p] Springfield Hospital, Chelmsford, UK; [q] Department of Academic Urology, The Royal Marsden Hospital NHS Foundation Trust, London, UK; [r] Department of Urology, Wrexham Maelor Hospital, Wrexham, UK; [s] North Bristol NHS Trust, Westbury on Trym, Bristol, UK; [t] Department of Urology, The Princess Alexandra Hospital NHS Trust, Harlow, UK; [u] Princess Grace Hospital, London, UK; [v] King Edward VII Hospital, London, UK; [w] Cromwell Hospital, London, UK; [x] Department of Urology, Ain Shams University Hospitals, Cairo, Egypt

TULSA

- Thermal ultrasound energy
- Transurethral delivery
  - Reduce risk of damage to rectum, sphincter, NVB
  - Shape ablation to prostate anatomy
- MRI guided
  - Image-based planning
  - Real-time MRI thermometry – treatment control

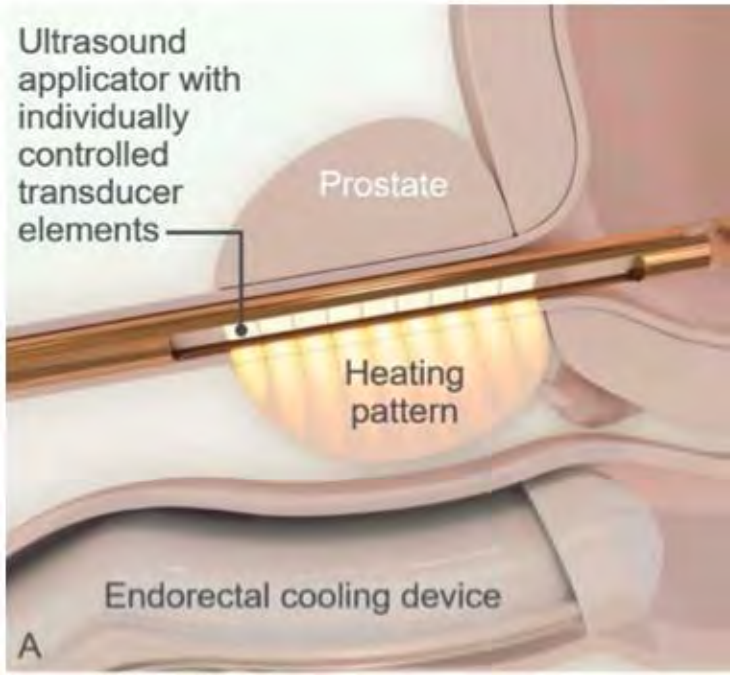

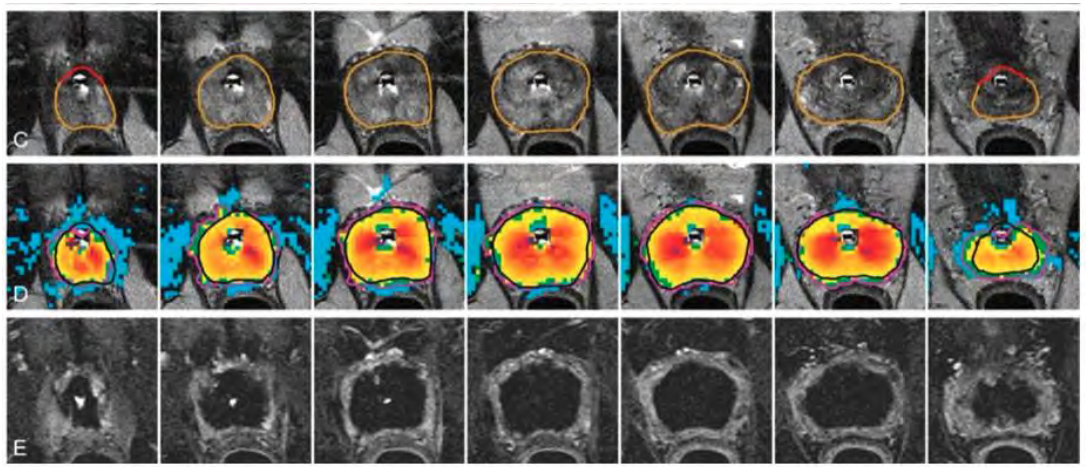

Chin et al. EurUrol 2016
Klotz et al. JU 2021

THE JOURNAL of UROLOGY
www.auajournals.org/journal/juro

OPEN

Magnetic Resonance Imaging-Guided Transurethral Ultrasound Ablation of Prostate Cancer

Laurence Klotz,* Christian P. Pavlovich, Joseph Chin, Gencay Hatiboglu, Michael Koch, David Penson, Steven Raman, Aytekin Oto, Jurgen Fütterer, Marc Serrallach, James Relle, Yair Lotan, Axel Heidenreich, David Bonekamp, Masoom Haider, Temel Tirkes, Sandeep Arora, Katarzyna J. Macura, Daniel N. Costa, Thorsten Persigehl, Allan J. Pantuck, Joyce Bomers, Mathieu Burtnyk,† Robert Staruch† and Scott Eggener

From Sunnybrook Health Sciences Centre (LK), University of Toronto, Johns Hopkins (CPP), University of Western Ontario (JC), University Hospital Heidelberg (GH, DB), German Cancer Research Center (DKFZ), Indiana University (MK, TT), Vanderbilt University Medical Center (DP, SA), UCLA Health Sciences (SR, AJP), University of Chicago (AO, SE), Radboud University Medical Center (JF, JB), ResoFus Alomar (Hospital Universitari De Bellvitge) (MS), Beaumont Health System (JR), UT Southwestern Medical Center (YL, DNC), University Hospital Cologne (AH), Joint Dept of Medical Imaging (MH), Sinai Health System, Sunnybrook Research Institute, Lunenfeld Tanenbaum Research Institute and University of Toronto, Toronto, Canada, Johns Hopkins University (KJM), Profound Medical (MB, RS)

Purpose: Magnetic resonance imaging-guided transurethral ultrasound ablation uses directional thermal ultrasound under magnetic resonance imaging thermometry feedback control for prostatic ablation. We report 12-month outcomes from a prospective multicenter trial (TACT).

Materials and Methods: A total of 115 men with favorable to intermediate risk prostate cancer across 13 centers were treated with whole gland ablation sparing the urethra and apical sphincter. The co-primary 12-month endpoints were safety and efficacy.

Results: In all, 72 (63%) had grade group 2 and 77 (67%) had NCCN® intermediate risk disease. Median treatment delivery time was 51 minutes with 98% (IQR 95–99) thermal coverage of target volume and spatial ablation precision of ±1.4 mm on magnetic resonance imaging thermometry. Grade 3 adverse events occurred in 9 (8%) men. The primary endpoint (U.S. Food and Drug Administration mandated) of prostate specific antigen reduction ≥75% was achieved in 110 of 115 (96%) with median prostate specific antigen reduction of 95% and nadir of 0.34 ng/ml. Median prostate volume decreased from 37 to 3 cc. Among 68 men with pretreatment grade group 2 disease, 52 (79%) were free of grade group 2 disease on 12-month biopsy. Of 111 men with 12-month biopsy data, 72 (65%) had no evidence of cancer. Erections (International Index of Erectile Function question 2 score 2 or greater) were maintained/regained in 69 of 92 (75%). Multivariate predictors of persistent grade group 2 at 12 months included intraprostatic calcifications at screening, suboptimal magnetic resonance imaging thermal coverage of target volume and a PI-RADS™ 3 or greater lesion at 12-month magnetic resonance imaging ($p < 0.05$).

Conclusions: The TACT study of magnetic resonance imaging-guided transurethral ultrasound whole gland ablation in men with localized prostate cancer

Abbreviations and Acronyms

ED = erectile dysfunction
GG = grade group
IIEF-15 = International Index of Erectile Function
IPSS = International Prostate Symptom Score
MID = minimally important difference
MRI = magnetic resonance imaging
PSA = prostate specific antigen
TACT = TULSA-PRO Ablation Clinical Trial
TULSA = transurethral ultrasound ablation

63% GG2 at baseline

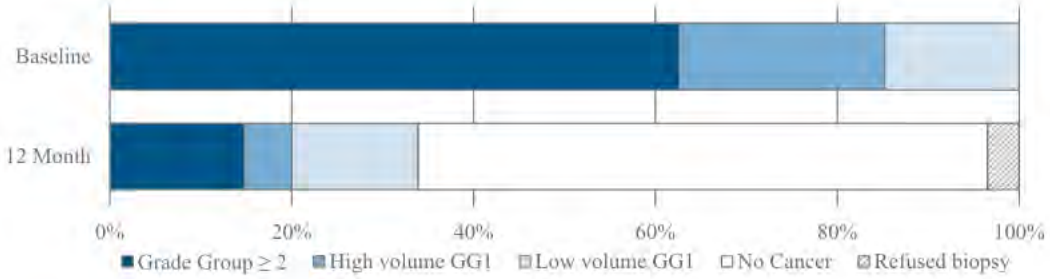

- 96% significant PSA reduction
- PSA nadir 0.34 ng/ml
- 79% free of GG2 at 12 months
- 65% no evidence of cancer

EUROPEAN UROLOGY 70 (2016) 447–455

available at www.sciencedirect.com
journal homepage: www.europeanurology.com

European Association of Urology

Platinum Priority – Prostate Cancer

Editorial by Herbert Lepor on pp. 456–457 of this issue

Magnetic Resonance Imaging–Guided Transurethral Ultrasound Ablation of Prostate Tissue in Patients with Localized Prostate Cancer: A Prospective Phase 1 Clinical Trial

Joseph L. Chin [a,], Michele Billia [a], James Relle [b], Matthias C. Roethke [c], Ionel V. Popeneciu [d], Timur H. Kuru [d], Gencay Hatiboglu [d], Maya B. Mueller-Wolf [c], Johann Motsch [d], Cesare Romagnoli [a], Zahra Kassam [a], Christopher C. Harle [a], Jason Hafron [b], Kiran R. Nandalur [b], Blaine A. Chronik [a], Mathieu Burtnyk [e], Heinz-Peter Schlemmer [c], Sascha Pahernik [d]*

[a] University of Western Ontario, London Health Sciences Centre, London, ON, Canada; [b] Beaumont Health System, Royal Oak, MI, USA; [c] German Cancer Research Center (DKFZ), Heidelberg, Germany; [d] University Hospital Heidelberg, Heidelberg, Germany; [e] Profound Medical Inc., Toronto, ON, Canada

Article info

Article history:
Accepted December 16, 2015

Associate Editor:
Stephen Boorjian

Keywords:
Prostate cancer
Ultrasound ablation
Magnetic resonance imaging
Image-guided intervention
Minimally invasive
Transurethral
Phase 1 clinical trial

Abstract

Background: Magnetic resonance imaging–guided transurethral ultrasound ablation (MRI-TULSA) is a novel minimally invasive technology for ablating prostate tissue, potentially offering good disease control of localized cancer and low morbidity.
Objective: To determine the clinical safety and feasibility of MRI-TULSA for whole-gland prostate ablation in a primary treatment setting of localized prostate cancer (PCa).
Design, setting, and participants: A single-arm prospective phase 1 study was performed at three tertiary referral centers in Canada, Germany, and the United States. Thirty patients (median age: 69 yr; interquartile range [IQR]: 67–71 yr) with biopsy-proven low-risk (80%) and intermediate-risk (20%) PCa were treated and followed for 12 mo.
Intervention: MRI-TULSA treatment was delivered with the therapeutic intent of conservative whole-gland ablation including 3-mm safety margins and 10% residual viable prostate expected around the capsule.
Outcome measurements and statistical analysis: Primary end points were safety (adverse events) and feasibility (technical accuracy and precision of conformal thermal ablation). Exploratory outcomes included quality of life, prostate-specific antigen (PSA), and biopsy at 12 mo.
Results and limitations: Median treatment time was 36 min (IQR: 26–44) and prostate

- Common adverse events
  - Hematuria (mild) 50%
  - UTI 33%
  - Epididymitis 3%
  - Prolonged catheterization 27%
- 12 months outcomes
  - 100% pad-free
  - 97% leak-free
  - 1 urethral stricture resolved with dilator

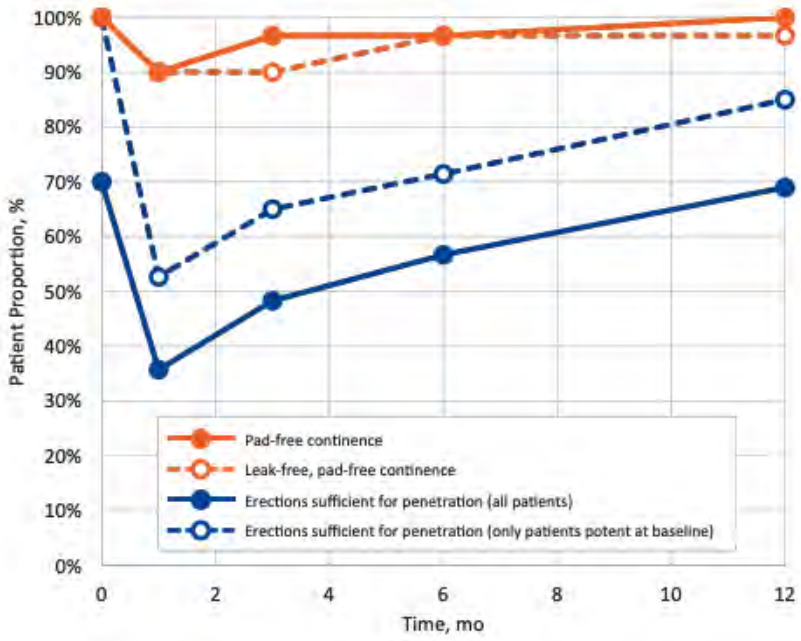

THE JOURNAL of UROLOGY
www.auajournals.org/journal/juro

OPEN

Magnetic Resonance Imaging-Guided Transurethral Ultrasound Ablation of Prostate Cancer

Laurence Klotz,* Christian P. Pavlovich, Joseph Chin, Gencay Hatiboglu, Michael Koch, David Penson, Steven Raman, Aytekin Oto, Jurgen Fütterer, Marc Serrallach, James Relle, Yair Lotan, Axel Heidenreich, David Bonekamp, Masoom Haider, Temel Tirkes, Sandeep Arora, Katarzyna J. Macura, Daniel N. Costa, Thorsten Persigehl, Allan J. Pantuck, Joyce Bomers, Mathieu Burtnyk,† Robert Staruch† and Scott Eggener

From Sunnybrook Health Sciences Centre (LK), University of Toronto, Johns Hopkins (CPP), University of Western Ontario (JC), University Hospital Heidelberg (GH, DB), German Cancer Research Center (DKFZ), Indiana University (MK, TT), Vanderbilt University Medical Center (DP, SA), UCLA Health Sciences (SR, AJP), University of Chicago (AO, SE), Radboud University Medical Center (JF, JB), ResoFus Alomar (Hospital Universitari De Bellvitge) (MS), Beaumont Health System (JR), UT Southwestern Medical Center (YL, DNC), University Hospital Cologne (AH), Joint Dept of Medical Imaging (MH), Sinai Health System, Sunnybrook Research Institute, Lunenfeld Tanenbaum Research Institute and University of Toronto, Toronto, Canada, Johns Hopkins University (KJM), Profound Medical (MB, RS)

Purpose: Magnetic resonance imaging-guided transurethral ultrasound ablation uses directional thermal ultrasound under magnetic resonance imaging thermometry feedback control for prostatic ablation. We report 12-month outcomes from a prospective multicenter trial (TACT).

Materials and Methods: A total of 115 men with favorable to intermediate risk prostate cancer across 13 centers were treated with whole gland ablation sparing the urethra and apical sphincter. The co-primary 12-month endpoints were safety and efficacy.

Results: In all, 72 (63%) had grade group 2 and 77 (67%) had NCCN® intermediate risk disease. Median treatment delivery time was 51 minutes with 98% (IQR 95–99) thermal coverage of target volume and spatial ablation precision of ±1.4 mm on magnetic resonance imaging thermometry. Grade 3 adverse events occurred in 9 (8%) men. The primary endpoint (U.S. Food and Drug Administration mandated) of prostate specific antigen reduction ≥75% was achieved in 110 of 115 (96%) with median prostate specific antigen reduction of 95% and nadir of 0.34 ng/ml. Median prostate volume decreased from 37 to 3 cc. Among 68 men with pretreatment grade group 2 disease, 52 (79%) were free of grade group 2 disease on 12-month biopsy. Of 111 men with 12-month biopsy data, 72 (65%) had no evidence of cancer. Erections (International Index of Erectile Function question 2 score 2 or greater) were maintained/regained in 69 of 92 (75%). Multivariate predictors of persistent grade group 2 at 12 months included intraprostatic calcifications at screening, suboptimal magnetic resonance imaging thermal coverage of target volume and a PI-RADS™ 3 or greater lesion at 12-month magnetic resonance imaging ($p < 0.05$).

Conclusions: The TACT study of magnetic resonance imaging-guided transurethral ultrasound whole gland ablation in men with localized prostate cancer

Abbreviations and Acronyms

ED = erectile dysfunction

GG = grade group

IIEF-15 = International Index of Erectile Function

IPSS = International Prostate Symptom Score

MID = minimally important difference

MRI = magnetic resonance imaging

PSA = prostate specific antigen

TACT = TULSA-PRO Ablation Clinical Trial

TULSA = transurethral ultrasound ablation

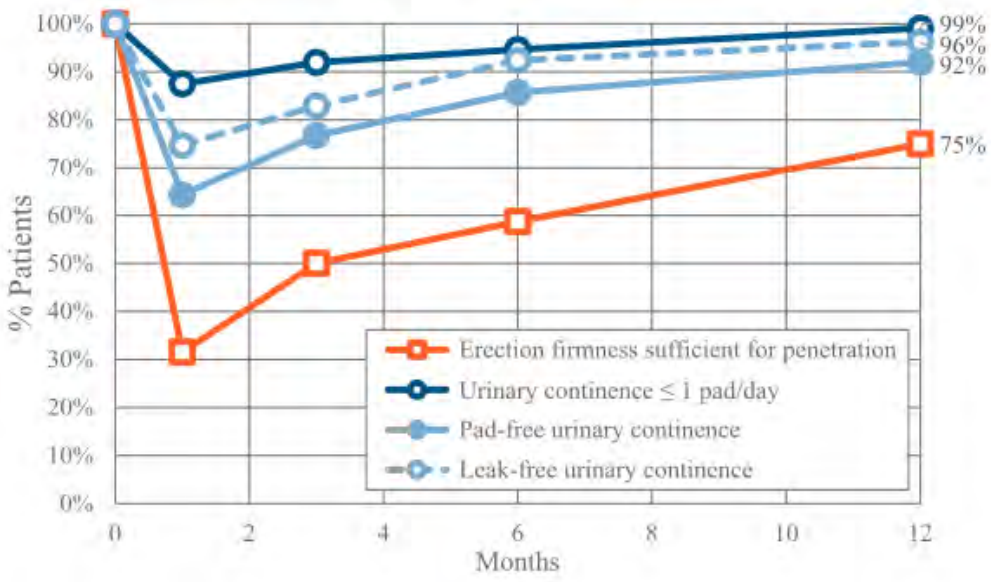

Irreversible Electroporation (IRE)

- IRE system delivers **low energy electrical pulses to create defects** in cell membranes, resulting in loss of homeostasis and subsequent cell apoptosis

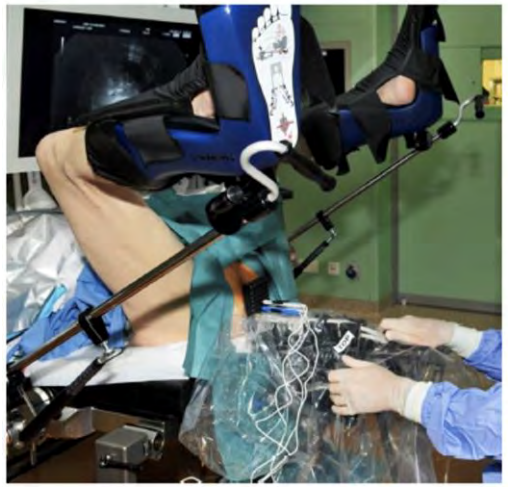



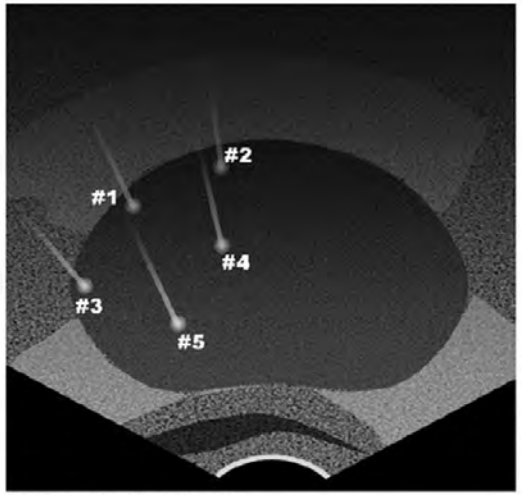



Images courtesy of AngioDynamics

available at www.sciencedirect.com
journal homepage: euoncology.europeanurology.com

European Association of Urology

Oncological and Quality-of-life Outcomes Following Focal Irreversible Electroporation as Primary Treatment for Localised Prostate Cancer: A Biopsy-monitored Prospective Cohort

Alexandar Blazevski [a,b,c,*], *Matthijs J. Scheltema* [a,b,d], *Brian Yuen* [a,b], *Natasha Masand* [b,c], *Tuan V. Nguyen* [b,c,e], *Warick Delprado* [f], *Ron Shnier* [g], *Anne-Maree Haynes* [b], *Thomas Cusick* [b], *James Thompson* [a,b,c], *Phillip Stricker* [a,b,c]

[a] St. Vincent's Prostate Cancer Centre, Darlinghurst, NSW, Australia; [b] Garvan Institute of Medical Research and Kinghorn Cancer Centre, Darlinghurst, NSW, Australia; [c] St Vincent's Clinical School, UNSW, Sydney, Australia; [d] Amsterdam UMC, Amsterdam, The Netherlands; [e] School of Biomedical Engineering, University of Technology, Sydney, NSW, Australia; [f] Douglas Hanly Moir Pathology, Macquarie Park, NSW, Australia; [g] I-MED Radiology, Sydney, NSW, Australia

Article info

Article history:
Accepted April 16, 2019

Associate Editor:
Gianluca Giannarini

Keywords:
Focal therapy
Irreversible electroporation
Multiparametric magnetic resonance imaging
Nanoknife
Prostate cancer

Abstract

Background: Focal irreversible electroporation (IRE) can be used to treat men with localised prostate cancer (PCa) with reduced impact on quality of life (QoL).
Objective: To assess oncological and functional outcomes.
Design, setting, and participants: To report on a prospective database of patients undergoing primary IRE between February 2013 and August 2018. A minimum of 12-mo follow-up was available for 123 patients. Median follow-up was 36 mo (interquartile range [IQR] 24–52 mo). A total of 112 (91%) patients had National Comprehensive Cancer Network intermediate risk and 11 (9%) had low risk. A total of 12 (9.8%) had International Society of Urological Pathology (ISUP) grade 1, 88 (71.5%) had ISUP 2, and 23 (18.7%) had ISUP 3.
Intervention: Focal IRE ablation of PCa lesions.
Outcome measurements and statistical analysis: Follow-up involved serial prostate-specific antigen (PSA), multiparametric magnetic resonance imaging (mpMRI), and transperineal template mapping biopsy (TTMB) at 12 mo. Failure-free survival (FFS) was defined as progression to whole-gland or systemic treatment or metastasis/death. Functional outcomes were assessed.
Results and limitations: Median age was 68 yr (IQR 62–73 yr). Median preoperative PSA was 5.7 ng/ml (IQR 3.8–8.0 ng/ml). On post-treatment TTMB, in-field recurrence was present in 2.7–9.8% of patients. FFS at 3 yr was 96.75%, metastasis-free survival 99%, and overall survival 100%. A total of 18 patients required

- 123 patient – Feb 2013– Sept 2018
- **91% intermediate risk** disease
- **36 months** median follow-up
- In-field recurrence **9.8%** at 12 mo
- Out-of-field recurrence **12%** at 12 mo
- 4.8% underwent salvage treatment
- FFS 97% at 3 years

available at www.sciencedirect.com
journal homepage: euoncology.europeanurology.com

European Association of Urology

Oncological and Quality-of-life Outcomes Following Focal Irreversible Electroporation as Primary Treatment for Localised Prostate Cancer: A Biopsy-monitored Prospective Cohort

Alexandar Blazevski [a,b,c,*], *Matthijs J. Scheltema* [a,b,d], *Brian Yuen* [a,b], *Natasha Masand* [b,c], *Tuan V. Nguyen* [b,c,e], *Warick Delprado* [f], *Ron Shnier* [g], *Anne-Maree Haynes* [b], *Thomas Cusick* [b], *James Thompson* [a,b,c], *Phillip Stricker* [a,b,c]

[a] St. Vincent's Prostate Cancer Centre, Darlinghurst, NSW, Australia; [b] Garvan Institute of Medical Research and Kinghorn Cancer Centre, Darlinghurst, NSW, Australia; [c] St Vincent's Clinical School, UNSW, Sydney, Australia; [d] Amsterdam UMC, Amsterdam, The Netherlands; [e] School of Biomedical Engineering, University of Technology, Sydney, NSW, Australia; [f] Douglas Hanly Moir Pathology, Macquarie Park, NSW, Australia; [g] I-MED Radiology, Sydney, NSW, Australia

Article info

Article history:
Accepted April 16, 2019

Associate Editor:
Gianluca Giannarini

Keywords:
Focal therapy
Irreversible electroporation
Multiparametric magnetic resonance imaging
Nanoknife
Prostate cancer

Abstract

Background: Focal irreversible electroporation (IRE) can be used to treat men with localised prostate cancer (PCa) with reduced impact on quality of life (QoL).
Objective: To assess oncological and functional outcomes.
Design, setting, and participants: To report on a prospective database of patients undergoing primary IRE between February 2013 and August 2018. A minimum of 12-mo follow-up was available for 123 patients. Median follow-up was 36 mo (interquartile range [IQR] 24–52 mo). A total of 112 (91%) patients had National Comprehensive Cancer Network intermediate risk and 11 (9%) had low risk. A total of 12 (9.8%) had International Society of Urological Pathology (ISUP) grade 1, 88 (71.5%) had ISUP 2, and 23 (18.7%) had ISUP 3.
Intervention: Focal IRE ablation of PCa lesions.
Outcome measurements and statistical analysis: Follow-up involved serial prostate-specific antigen (PSA), multiparametric magnetic resonance imaging (mpMRI), and transperineal template mapping biopsy (TTMB) at 12 mo. Failure-free survival (FFS) was defined as progression to whole-gland or systemic treatment or metastasis/death. Functional outcomes were assessed.
Results and limitations: Median age was 68 yr (IQR 62–73 yr). Median preoperative PSA was 5.7 ng/ml (IQR 3.8–8.0 ng/ml). On post-treatment TTMB, in-field recurrence was present in 2.7–9.8% of patients. FFS at 3 yr was 96.75%, metastasis-free survival 99%, and overall survival 100%. A total of 18 patients required

- 22% experienced grade 2 complications
  - (UTI, urgency, frequency, incontinence)
- 99% pad-free
- 73% no change in erectile function

Patient Selection

DISEASE FACTORS

- Intermediate risk (no EPE, no SVI)
- Index lesion visible on MRI
- Systematic and targeted biopsy results consistent with MRI findings

PATIENT FACTORS

- Reasonable life-expectancy
- Able to go under general anesthesia (For IRE, able to tolerate pancuronium bromide, atracurium or cisatracurium)
- Does not desire fertility
- Able to catheterize (stricture/bladder neck contracture)
- Able to visualize prostate on TRUS
- Understands the lack of long-term data in the focal therapy space

Risk and Complications Profile for Focal Treatments

Cryotherapy	Possible side effects of cryosurgical ablation include but not limited to urinary retention at a rate of 5% probability, genital swelling, penile paresthesia, **erectile dysfunction** at 50% probability, urethral sloughing, urethral obstruction at a rate of approximately 5%, rectal pain, **urinary incontinence** at a rate of 5% probability and development of a fistula at a rate of 1-3% probability.
HIFU (High Intensity Focused Ultrasound)	The most common side effects are urinary problems (urgency, frequency, **leakage of urine**), recurrence of cancer and difficulty getting or keeping an erection (**erectile dysfunction**), some may experience a light tingling sensation of the treated area may persist for a few weeks. Having HIFU more than once may increase your risk of urinary problems, but it doesn't appear to increase your risk of other side effects.

Risk and Complication Profile for Focal Treatments Cont'd

IRE (Irreversible Electroporation)	This ablative treatment attempts to preserve surrounding structures reducing severe side effects **like incontinence** or **impotence.** Risk of incontinence is 1% and impotence risk is 10%.
TULSA (Transurethral Ultrasound Ablation)	Pain/discomfort in the ablation area, blood in urine, urinary tract infection, **urinary incontinence, and erectile dysfunction.** A 20-25% incidence of erectile dysfunction and a 2.6% incidence of moderate to severe urinary incontinence.

Post Operative Expectations

- Feelings of tiredness more than normal related to the anesthesia.
- Foley catheter in place for 5-7 days and may be removed at home with direction from a nurse. If patient is not comfortable with removal at home, then may come into the office.
- May have blood with clots in urine for the next few days (1-3 days on average) postoperatively. Hydration is key.
- Patient may experience bladder spams and or burning with urination for 5-7 days after the procedure.
- Urine flow may be slower than usual for about 2-3 weeks after the procedure.
- May experience soreness and bruising in the perineum and or scrotum.

How Do We Do Follow up?

Routine follow-up comprised of PSA-tests and MRI scans. PSA testing is recommended 1-, 3- and 6-months post procedure. MRI prostate post procedure at 6 and 18 months then repeat prostate biopsy at 6 months. If PSA is stable and Prostate MRI are negative, then the patient may forego a prostate biopsy. Complete AUA and SHIM form at each follow up visit until symptoms stabilize.

Oh No Recurrence

Biochemical recurrences are defined by a rise in PSA above the baseline value at 6 months post focal treatments with confirmation by multi-parametric MRI, in some cases by additional biopsy or PSMA-PET/CT.

Case 1

- 62 M
- PMH: Colorectal cancer s/p sigmoidectomy and adjuvant FOLFOX and NED >5 years
- No FH prostate cancer
- HPI: referred for elevated PSA
- PSA History:
  - 07/2021: 6.25
  - 01/2022: 7.5
- DRE deferred
- AUA 9
- SHIM 19

Pre-op MRI

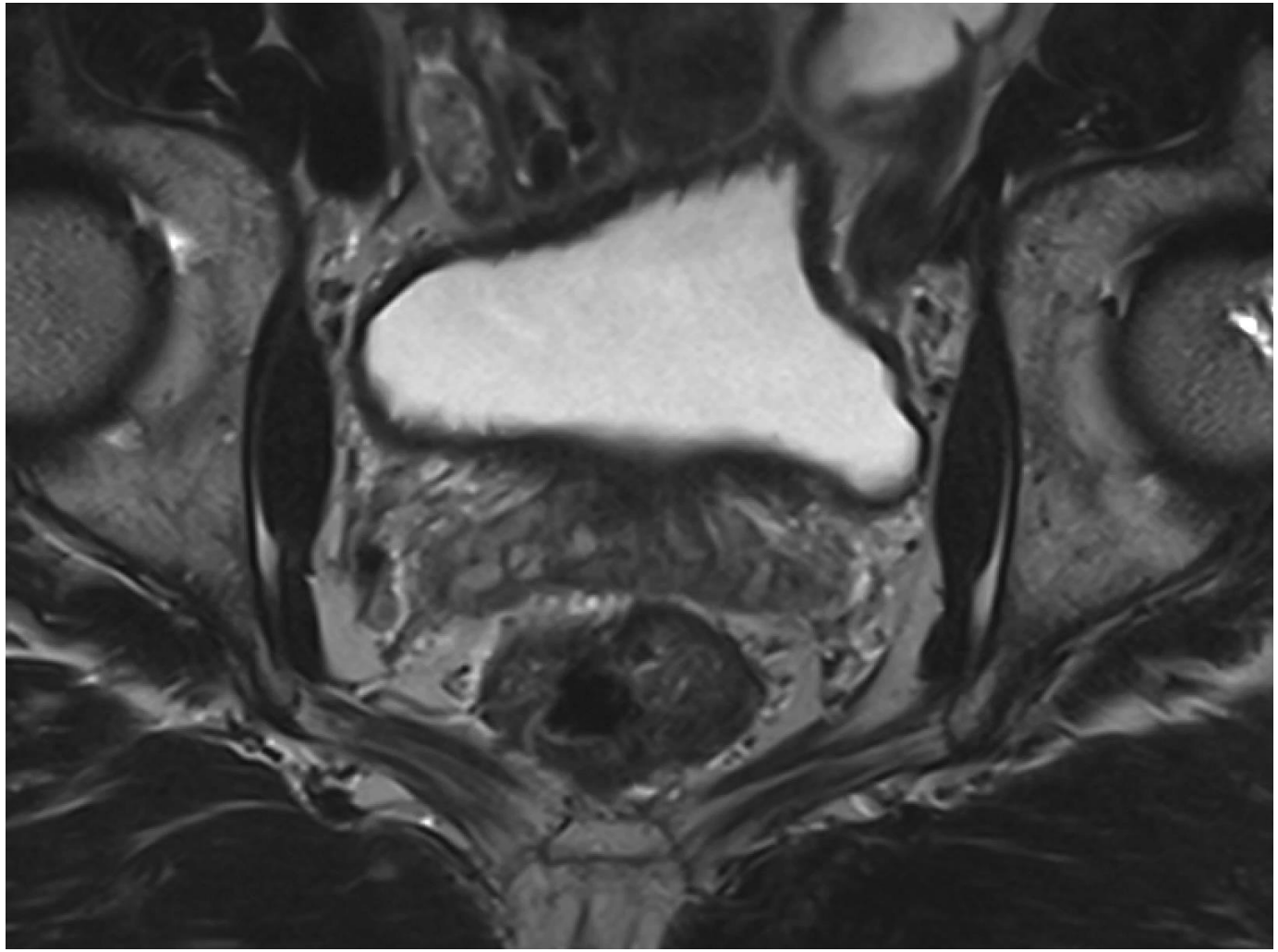

Pre-op MRI

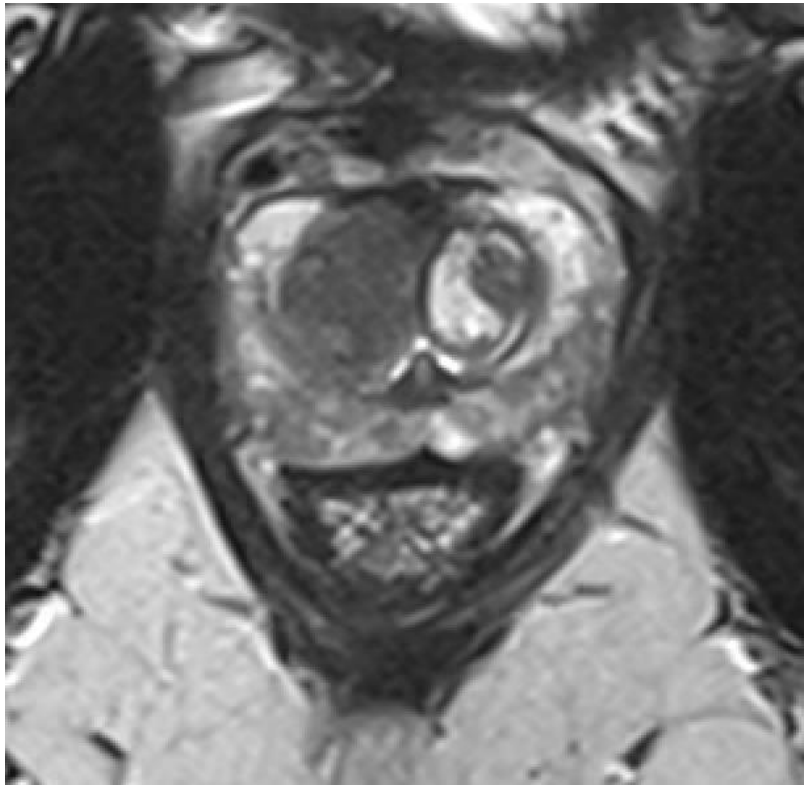

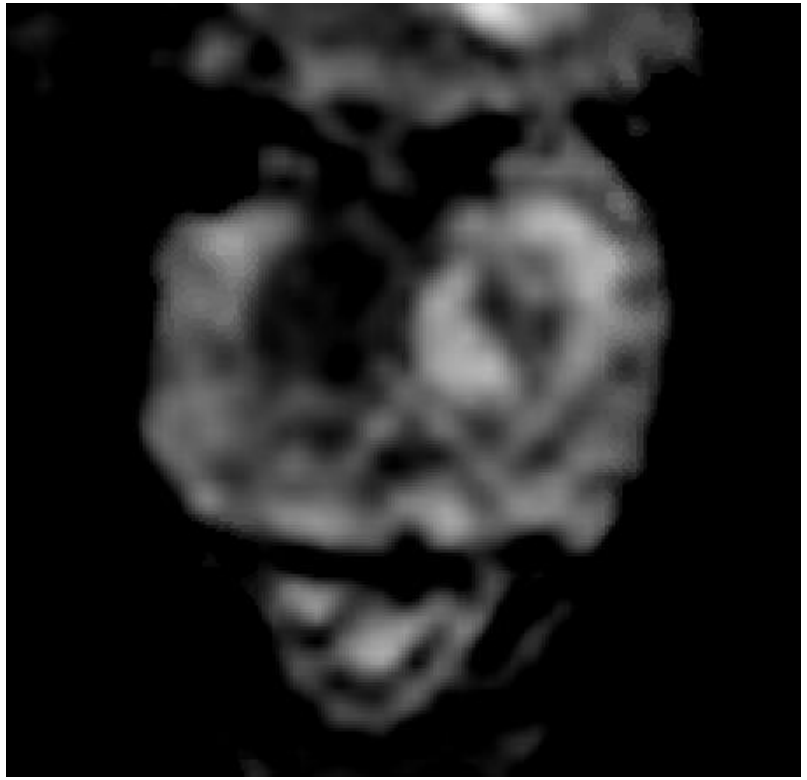

- PV 21g
- PIRADS 5 lesion
- Right transition zone from base to apex
- T2: Hypointense
- ADC: Hypointense
- DCE: positive

Prostate biopsy

C. PROSTATE, **RIGHT MID**; NEEDLE CORE BIOPSY:

- Prostatic adenocarcinoma**, Gleason grade 3+4=7** (Grade group 2), two foci (< 1mm, and < 1 mm) involving <5% of the core.
- Carcinoma focus is too small to accurately assign Gleason pattern 4 percentage..

D. PROSTATE**, RIGHT APEX**; NEEDLE CORE BIOPSY:

- Prostatic adenocarcinoma, **Gleason grade 3+4=7** (Grade group 2), 1.5 mm focus involving 10% of the core.
- Gleason pattern 4 is 35% of the tumor.

E. PROSTATE, **RIGHT LATERAL MD**; NEEDLE CORE BIOPSY:

- Prostatic adenocarcinoma, **Gleason grade 3+4=7** (Grade group 2), 2 mm focus involving 20% of the involved core.
- Gleason pattern 4 is 10% of the tumor.
- Tumor involves 1 of 2 cores.

- All other cores benign

Patient underwent IRE

IRE on 5/6/2022

Post-op

5/25/2022: reported weak stream (PVR 5cc), some burning with urination, poor erections

9/13/2022: LUTS resolved, able to achieve erections with Tadalafil

12/13/2022: LUTS resolved, able to achieve erections with Tadalafil

PSA History:

- 07/2021: 6.25
- 01/2022: 7.5
- IRE
- 09/2022: 2.15
- 12/2022: 1.51
- 03/2023: 1.74

Post-op MRI

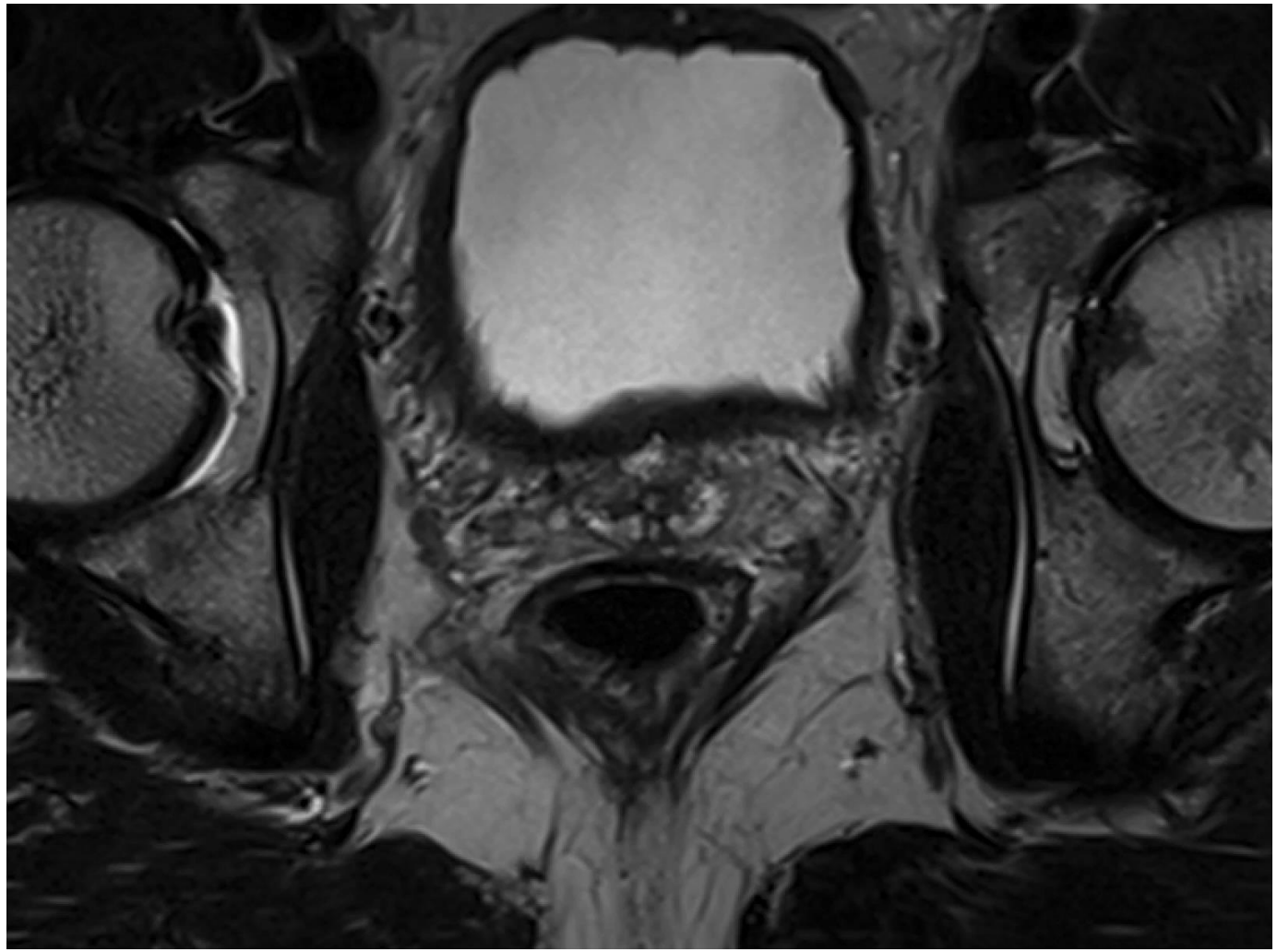

Post-op MRI

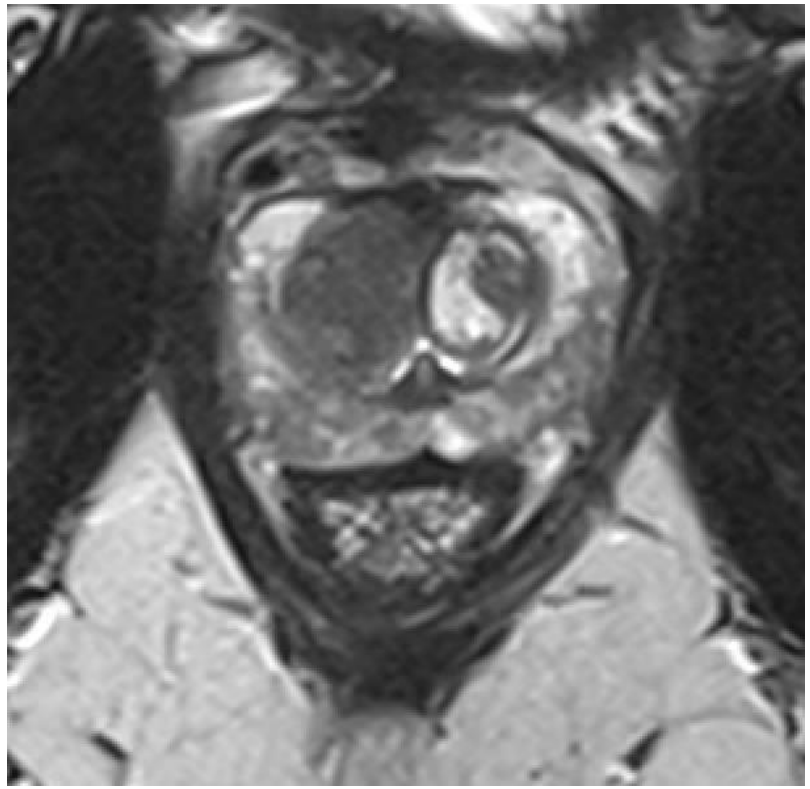

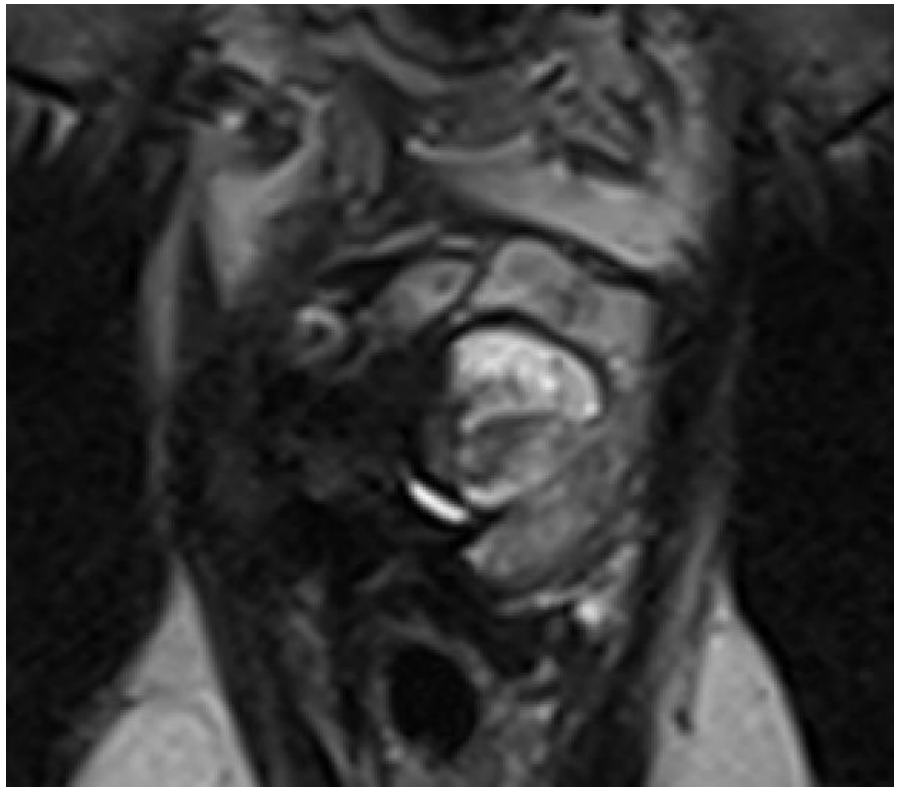

- Fibrosis
- Volume loss
- No diffusion restriction
- No enhancement

- Repeat biopsy: benign

Challenges moving forward…

- Long-term data – oncologic outcomes
- Which energy modality is better?
- Data on salvage options
- Standardize follow-up, uniform nomenclature

EUROPEAN UROLOGY 78 (2020) 371–378

available at www.sciencedirect.com
journal homepage: www.europeanurology.com

European Association of Urology

Platinum Priority – Prostate Cancer

Editorial by Marcus G. Cumberbatch and Declan G. Murphy on pp. 379–380 of this issue

Standardized Nomenclature and Surveillance Methodologies After Focal Therapy and Partial Gland Ablation for Localized Prostate Cancer: An International Multidisciplinary Consensus

Amir H. Lebastchi[a,†], Arvin K. George[b,†], Thomas J. Polascik[c], Jonathan Coleman[d], Jean de la Rosette[e], Baris Turkbey[f], Bradford J. Wood[g], Michael A. Gorin[h,i], Abhinav Sidana[j], Sangeet Ghai[k], Kae Jack Tay[l], John F. Ward[m], Rafael Sanchez-Salas[n], Berrend G. Muller[o], Bernard Malavaud[p], Pierre Mozer[q], Sebastien Crouzet[r], Peter L. Choyke[f], Osamu Ukimura[s], Ardeshir R. Rastinehad[t], Peter A. Pinto[a,]*